

 <p>ISSN NO. 2320-5407</p>	<p>Journal Homepage: -<a href="http://www.journalijar.com">www.journalijar.com</a></p> <h2 style="text-align: center;">INTERNATIONAL JOURNAL OF ADVANCED RESEARCH (IJAR)</h2> <p style="text-align: center;">Article DOI:10.21474/IJAR01/8073 DOI URL: <a href="http://dx.doi.org/10.21474/IJAR01/8073">http://dx.doi.org/10.21474/IJAR01/8073</a></p>	
---	--	---

### RESEARCH ARTICLE

#### A RARE TYPE OF INTERNAL HERNIA: A CASE REPORT AND LITERATURE REVIEW.

**Faisal El mouhafid, Nouredine Njoumi, Mohamed Najih, Aziz Fadili, Hicham Iraki, Mountassir Moujahid, Abdelkader Ihirchiou, Abdelmounim Aitali and Aziz Zentar.**

Faisal El mouhafid, Department of Visceral Surgery II, Mohammed V Military Teaching Hospital, Ryad, Rabat, Morocco.

#### Manuscript Info

##### Manuscript History

Received: 11 September 2018

Final Accepted: 13 October 2018

Published: November 2018

#### Abstract

Foramen of Winslow hernia is a rare occurrence, accounting for only 8% of all internal hernias and 0.08% of all hernias. It presents a diagnostic challenge with subtle clinical and radio - logical features. The rate of preoperative diagnosis has been reported to be <10% of the intraoperatively confirmed cases. A delay in diagnosis and treatment is often observed and may be responsible for the high mortality rate of up to 49% .

Here we describe a case of a 67-year-old man who presented with acute epigastric pain. A CT scan was suggested the diagnosis of an internal hernia. At laparotomy, the herniated small bowel was viable and reduction was achieved with gentle traction.

Successful management of foramen of Winslow hernia requires prompt diagnosis and surgical treatment.

*Copy Right, IJAR, 2018,. All rights reserved.*

#### Introduction:-

Internal abdominal hernia (IH) is a protrusion of intestines or other abdominal organs through a normal or abnormal orifice in the peritoneum or mesentery, occasionally leading to strangulation or incarceration. Ordinarily, hernias develop in a pre-existing anatomical orifice, such as the foramen of Winslow, Congenital anomalies due to improper intestinal rotation, previous trauma, vascular or inflammatory diseases, or postsurgical iatrogenic are predisposed factors to internal herniation. Internal hernias are a rare cause of acute abdomen and intestinal obstruction in adults. IH has a reported autopsy incidence of 0.2 to 0.9% and is the cause of small bowel obstruction in 0.6 to 5.8% of the cases [1]. However, if strangulated and left untreated, internal hernias have an overall mortality greater than 50% [2]. Internal abdominal hernias present a nonspecific and intermittent clinical presentation, therefore presurgical diagnosis is rare. We describe here a case of a rare type of internal hernia presenting as acute intestinal obstruction in a 67-year-old male.

#### Case Presentation:-

A 67-year-old male was admitted to the emergency department with progressive dull abdominal pain and distension with nausea, vomiting for the last three days. There was no history of any comorbid illness, past surgical intervention, or trauma.

#### Corresponding Author:-Faisal El mouhafid.

Address:-Faisal El mouhafid, Department of Visceral Surgery II, Mohammed V Military Teaching Hospital, Ryad, Rabat, Morocco.

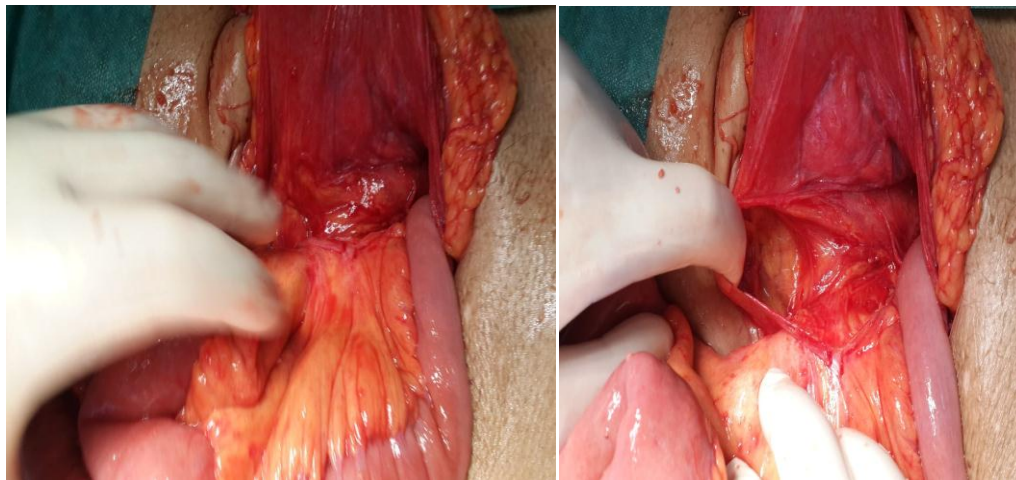
General examination, pulse rate was 89/minute and blood pressure was 130/80 mm of Hg. Patient was afebrile and tachypneic. Abdominal distension and tenderness were detected on abdominal examination. Digital rectal examination was normal. Rest systemic examination revealed no abnormality.

Full blood count, electrolytes, renal function, liver function and lipase were all normal.

Abdominal radiography in the upright position showed dilated small intestinal loops with multiple air-fluid levels suggesting intestinal obstruction. A CT scan was performed and suggested the diagnosis of an internal hernia with containing the small bowel

Surgical exploration was then performed using an open approach. On laparotomy, this confirmed a foramen of Winslow hernia. It contained the small bowel. After hernia reduction, all the intestine was viable (Figures 1;2 ).

The postoperative recovery was uneventful, and the patient was discharged after 4 days. There is no evidence of recurrence to date.



**Figures 1,2:**foramen of Winslow hernia

## Discussion:

Primary or congenital internal hernias in adults are extremely rare. Congenital internal abdominal hernias are either retroperitoneal or formed from congenital anomalous openings lacking a true peritoneal sac. Retroperitoneal hernias are further classified by Ghahremani into paraduodenal (30–53% ), foramen of Winslow (6%–10%), pericecal (10%–15%), intersigmoid (4%–8%), pelvic, and paravesical hernias (6%), where as hernias formed from congenital anomalous openings can be categorized as transmesenteric (8%–10%), broad ligament (4–7%), or transomental hernias (1–4%) [3].

Foramen of Winslow hernia can be defined as peculiar variant of internal abdominal hernia, since it is a normal peritoneal orifice kept closed by normal intra-abdominal pressure that may be permeated by the intra-abdominal viscera [4]. the first report in 1834 by Blandin in autopsies, <200 cases of foramen of Winslow hernia have been reported in the medical literature [ 5]. There are multiple anatomical abnormalities reported as possible predisposing factors for a visceral herniation through this foramen [ 6]: abnormally enlarged foramen; the presence of an unusually long small-bowel mesentery or persistence of the ascending mesocolon; an elongated right hepatic lobe, which could be directing the mobile intestinal loop into the foramen; a lack of fusion between caecum or ascending colon to the parietal peritoneum; a defect in the gastrohepatic ligament, incomplete intestinal rotations or malrotation. The rate of preoperative diagnosis has been reported to be <10% of the intraoperatively confirmed cases [5]. A delay in diagnosis and treatment is often observed and may be responsible for the high mortality rate of up to 49% associated with this hernia type. Internal hernia is often revealed by intestinal obstruction associated with non-viable bowel at the time of operation [7].

The clinical detection of an internal abdominal hernia is infrequent and symptomatology is unspecific.[8]Consequently, it is often confused with diverticulitis and colon cancer.[9]<sup>2</sup>In this case the constitutional symptoms such as abdominal pain and distension were very unspecific. In some very particular cases, the internal hernia through the Winslow hiatus is revealed by an obstructive jaundice due to compression of the hepatic pedicle [7].

The key to diagnosis relies on prompt radiologic studies and Computed tomography (CT) plays an important role in the evaluation of intestinal obstruction and acute abdomen [1]. Both radiographs and ultrasonography (23% detection) are poor in detecting the etiology of intestinal obstruction. Multidetector CT can identify the specific site and severity of obstruction, closed loop, and multiple segments of obstruction [10]. It determines the etiology as well by identifying internal hernias and extraluminal lesions. CT features of IH include observation of a saclike mass or cluster of dilated small bowel loops at an abnormal anatomic location in the presence of Small bowel obstruction and observation of an engorged, stretched, or displaced mesenteric vascular pedicle and of converging vessels at the hernia orifice [11]. Complications such as ischemia, necrosis, or perforation and inflammatory changes can also be established on multidetector CT [12]. CT scan is thus a valuable tool in the early diagnosis and planning of surgical exploration in patients with IH and radiologists need to be familiar with the characteristic CT findings. However, the CT diagnosis of IH remains difficult even after its disseminated accessibility and use [10].

Timely surgical intervention based on clinical suspicion and/or CT scan findings is warranted for the management of IH presenting with intestinal obstruction [2]. Reduction with simple and gentle traction of the strangulated intestinal segment should be done as early as possible to prevent intestinal ischemia, necrosis, and perforation and thereby reduce resection rates [13]. Occasionally, this can be difficult; in these situations the gastrocolic or gastrohepatic ligaments must be opened or, alternatively, a wide Kocher manoeuvre performed. In the case of massive colonic dilatation a colotomy for decompression with a suction device can be useful [14,15]. In the case of overt intestinal necrosis an adequate resection is obviously mandatory; nevertheless there is no clear and established consensus on surgical management when the herniated contents are grossly viable. Some surgeons report right colonic fixation or caecopexy to the lateral wall, whereas others advocate right colectomy especially when there is a lack of fusion between caecum or ascending colon to the parietal peritoneum in order to avoid subsequent volvulus [14].

some surgeons decide to definitively close the foramen of Winslow, but, That can lead to complications such as accretions and/or portal vein thrombosis. Thus, leaving the foramen open may be justifiable since the inflammatory post-operative adhesions will most often obliterate the foramen entrance with no evidence of recurrent herniation [4;15].

Recently laparoscopic technique has also been found to be useful for diagnosis and treatment of intestinal obstruction [1, 2].

## Conclusion:

Internal hernias are a rare cause of intestinal obstruction given the high mortality associated, nevertheless still often underdiagnosed. Primary internal hernias should be kept in the differential diagnosis of acute intestinal obstruction in adults without history of surgery or trauma. Physical examination findings are nonspecific; a high index of clinical suspicion along with urgent CT is suggested to aid in the preoperative diagnosis of IH. Early surgical treatment is crucial to avert the high risk of associated morbidity and mortality.

## References:-

1. E.-J. Jang, S. H. Cho, and D.-D. Kim, "A case of small bowel obstruction due to a paracecal hernia," *Journal of the Korean Society of Coloproctology*, vol. 27, no. 1, pp. 41–43, 2011. View at Publisher · View at Google Scholar · View at Scopus
2. Rae, A. Kalyanaraman, A. Ward, and A. Harikrishnan, "An interesting case of retrocaecal internal herniation causing small bowel obstruction," *Annals of Medicine and Surgery*, 2015. View at Publisher · View at Google Scholar
3. M. Takeda, Y. Ohnuki, T. Uchiyama, O. Kubota, and K. Ohishi, "Small intestinal strangulation due to a rare type of primary internal hernia," *International Surgery*, vol. 98, no. 4, pp. 409–411, 2013. View at Publisher · View at Google Scholar · View at Scopus

4. González R, Pardo P, Valeira E, Perez C, Santos R, Loves L, et al. Correct preoperative diagnosis of herniation through the foramen of Winslow: two case reports. *Hernia*. 2013;17:409–17. [PubMed]
5. Osvald AB, Mossman DF, Bersch VP, Rohde L. Intestinal obstruction caused by a foramen of Winslow hernia. *Am J Surg*. 2008;196:242–4. [PubMed]
6. Takeyama N, Gokan T, Ohgiya Y. Ct of internal hernias. *Radiographics*. 2005;25:997–1015. [PubMed]
7. Armstrong O, Hamel A, Grignon A, Peltier J, Hamal O, Letessier E, et al. Internal hernias: anatomical basis and clinical relevance. *SurgRadiol Anat*. 2007;29:333–7. [PubMed]
8. Blachar A., Federle M.P., Dodson S.F. Internal hernia: clinical and imaging findings in 17 patients with emphasis on CT criteria. *Radiology*. 2001;218:68–74. [PubMed]
9. Blachar A., Federle M., Brancatelli G., Peterson M.S., Oliver J.H., 3rd, Li W. Radiologist performance in the diagnosis of internal hernia by using specific CT findings with emphasis on mesenteric hernia. *Radiology*. 2001;221:422–428. [PubMed]
10. L. C. Martin, E. M. Merkle, and W. M. Thompson, “Review of internal hernias: radiographic and clinical findings,” *American Journal of Roentgenology*, vol. 186, no. 3, pp. 703–717, 2006. View at Publisher · View at Google Scholar · View at Scopus
11. N. Takeyama, T. Gokan, Y. Ohgiya et al., “CT of internal hernias,” *Radiographics*, vol. 25, no. 4, pp. 997–1015, 2005. View at Publisher · View at Google Scholar · View at Scopus
12. F. Lassandro, F. Iasiello, N. L. Pizza et al., “Abdominal hernias: radiological features,” *World Journal of Gastrointestinal Endoscopy*, vol. 3, no. 6, pp. 110–117, 2011. View at Google Scholar
13. R. Gomes and J. Rodrigues, “Spontaneous adult transmesenteric hernia with bowel gangrene,” *Hernia*, vol. 15, no. 3, pp. 343–345, 2011. View at Publisher · View at Google Scholar · View at Scopus
14. Farthouat P, Platel JP, et al. Hernie du hiatus de Winslow: diagnostic tomodensitométriquepréopératoireettraitement par coelioscopie. *Ann Chir*. 1998;52:387–9. [PubMed]
15. Kotobi H, Echaieb A, Gallot D. Traitement Chirurgical des HerniesRares. *Techniques Chirurgicales-Appareil Digestive EMC*. Paris: Elsevier SAS; 2005. pp. 40–5.