



Journal Homepage: - www.journalijar.com

INTERNATIONAL JOURNAL OF ADVANCED RESEARCH (IJAR)

Article DOI: 10.21474/IJAR01/10570

DOI URL: <http://dx.doi.org/10.21474/IJAR01/10570>



RESEARCH ARTICLE

THE DIFFERENTIAL DIAGNOSIS OF ACUTE KNEE INJURIES WITH HEMARTHROSIS

Majed S. Al. Sulaiman, Peter Rockborn, Turki M. Al. Mohaid, Salman A. Al. Harthi, Khaled M. Al. Shareef
and Qusai M. Al. Sulaiman

Manuscript Info

Manuscript History

Received: 22 December 2019

Final Accepted: 25 January 2020

Published: February 2020

Key words:

Hemarthrosis, ACL Injury, PCL Injury,
Lachman Test, Knee Injuries, Sports
Injuries

Abstract

Objectives: This study was performed to answer the following questions: First, does the knee examination under general anesthesia (GA) and arthroscopy allow a more accurate diagnosis? Second, what is the incidence and the differential diagnosis of injured knees with hemarthrosis.

Methods: This retrospective study was performed on 350 cases from a single center with complaints of knee pain and swelling.

Results: Seventy out of the 350 cases were selected based on inclusion and exclusion criteria. The average age was 30.6 years. The right knee was injured in 44.3%; left knee in 55.7%. A professional sport level was in 17.1%; a recreational was in 82.9%. Indirect injury caused 71% and 29% were caused by direct injury. Lachman test at emergency was positive in 38.6%; negative in 38.6%; difficult to perform in 17%; not examined in 5.7%. Under GA, Lachman test was positive in 81.4%; negative in 10%; not examined in 8.6%. Under arthroscopy: 94.3% had anterior cruciate ligament (ACL) tears; the ACL was intact in 5.7%; completely ruptured in 78.6% and partially ruptured in 15.7%. Isolated total ACL rupture was in 31.4%. Isolated partial ACL rupture was in 15.7%. Posterior cruciate ligament (PCL) partial rupture was in 2.9%. Meniscal tear was in 71.4%; lateral meniscal tear (LM) in 40% and medial meniscal tear (MM) in 31.4%. ACL + LM in 22.9%; ACL + MM in 8.6%; ACL + LM + MM in 4.3%; ACL + MM + LM + cartilage injury (CI) in 2.9%; ACL + MCL + LM in 2.9%.

Conclusion: Aspiration of hemarthrosis in a traumatic knee is a good indicator for ACL injury. ACL tear is the most common knee hemarthrosis injury and often occurs as an isolated ligamentous injury, and noted that combined injuries are infrequent causes of posttraumatic hemarthrosis.

Copy Right, IJAR, 2020,. All rights reserved.

Introduction:-

A patient presenting with a knee effusion, developing rapidly after injury, within four to six hours, is presumed to have hemarthrosis. An anterior cruciate ligament (ACL) injury is usually accompanied by rapid hemarthrosis, which generally occurs within three hours in approximately 80% of patients. ACL injuries may occur owing to a contact force; however, the most common mechanism for the injury is non-contact deceleration secondary to a valgus external rotation, varus internal rotation, or hyperextension. Arthrocentesis could be used as a diagnostic test and a therapeutic procedure. In a study by Wang et al. (1), joint aspiration might be able to lower pain score or raise the

sensitivity of physical examination for diagnostic acute ACL injury at follow up visit in orthopedic outpatient department. Knee joint aspiration in acute ACL injury with suspected hemarthrosis could be considered as a diagnostic procedure (1).

Among the non-invasive clinical diagnostic tests available to us, the Lachman test has proven to be the most reliable (2). The Lachman, anterior drawer, and pivot shift tests are used to establish a diagnosis of ACL deficiency (2). The uninjured knee should always be examined for a baseline comparison. The Lachman test is the most sensitive in a patient who is awake (3). The sensitivity of the Lachman test approaches 81% (3). When assessing the endpoint, the examiner feels for the ACL limiting the amount of shifting of the shin bone. Typically, an examiner will describe the endpoint as either "firm" or "soft." A firm endpoint implies the ACL is doing its job to limit the amount of movement in the knee joint. A soft endpoint is indicative of the ACL not functioning well and other structures (the secondary stabilizers) limiting the amount of movement in the joint.

The significance of the injury was first appreciated by Gillquist et al. (4), Noyes et al. (5), and DeHaven (6). Gillquist et al. (4), on the basis of a study on 69 knees, found that 59% of patients had an ACL tear that was diagnosed on preoperative examination in only 15% of patients. This percentage increased to 32% when the patients were examined under general anesthesia (GA).

In a study by Bomberg and McGinty (1990) (7), 72% of patients had an ACL injury and 62% had a meniscal injury, usually associated with an ACL tear (7). Only 24% of the complete ACL tears were diagnosed preoperatively. When these knees were examined in patients under GA, 56% of the complete ACL tears were diagnosed preoperatively.

In DeHaven's series (6) of 113 stable athletic injuries, 72% had an ACL tear, 15% had an isolated meniscal tear, and 6% had an osteochondral fracture, which was not detected on plain radiographs. DeHaven in 1980 (8) reported that the Lachman test was very reliable for the diagnosis of ACL tears and was expected to provide positive results in 85% of patients without anesthesia and in 100% of patients under GA.

This retrospective study was performed to define the current role of diagnostic arthroscopy for acute knee injury with post-traumatic hemarthrosis to answer the following questions:

1. Does the examination under GA and arthroscopy allow a more accurate diagnosis of injury to joint structures?
2. What is the differential diagnosis of hemarthrosis?

Patients and Methods:-

This retrospective study was performed on 350 cases admitted to Vrinnevi Hospital, Norrköping, Sweden, with complaints of knee pain and swelling during activities of daily living like sports, dance, etc. Study data were collected over 4 years. The study was approved by the Orthopedic department of Vrinnevi Hospital.

Selection of Patient files:

The patients' files were selected according to the code data program number of arthroscopies. We collected 350 files (all of the patients had undergone arthroscopy).

Inclusion and exclusion criteria:

All the 350 patients' medical records were filtered according to the inclusion and exclusion criteria. The inclusion criterion was pure blood aspirated from the injured knee. Patients with unclear blood (mixed with fat drops) aspirated from the knees were excluded.

Data Collection:

All data were collected retrospectively from patient files and arthroscopic findings [Table 1]. These protocols were completed by the operating surgeon directly post-operatively. Subsequently, these protocols were entered into a database. The knee injuries were classified. The patient's age, knee site, sport level, and mechanism of injury were registered.

Examination at emergency:

All patients were seen in the emergency department. Anteroposterior and lateral plain radiographs were taken in all cases. The presence of knee hemarthrosis was confirmed by needle aspiration. The aspiration process was performed

by an emergency doctor (consultant, specialist, or resident). Lachman test was performed if the patient could tolerate it.

Preoperative examination:

Preoperatively, the Lachman test was performed under GA in the operating room.

Arthroscopic examination:

This was performed under GA by the “knee team” (specialist and consultant). At arthroscopy, anterolateral and anteromedial portals were used; other portals were used as required. All the knee compartments were examined. Tourniquets were not used.

Arthroscopic ACL examination:

A blunt hook-shaped probe was used to examine the ACL through an appropriate entry portal. Tension of the ACL fibers was evaluated by pulling the ACL with a hook. ACL tears were classified as partial or complete on the basis of visual inspection and probing.

Meniscal injuries:

Meniscal tears have been classified based on appearance as longitudinal < 1 cm and > 1 cm, horizontal, radial, bucket-handle, and complex tears (9). All data were collected retrospectively using an arthroscopic protocol and were entered into a database. All other knee structures, such as the patella, posterior cruciate ligament (PCL), tibia, and femoral cartilage surfaces, were examined.

Data Analysis:

Statistica 7.1 - 2005, in Swedish language for the data analysis was used.

Results:-**Patient and injury characteristics:**

A total of 70 cases were selected based on our predefined inclusion and exclusion criteria. The average age of the patients was 30.6 (15–54) years. The right knee was injured in 31 (44.3%), while the left knee in 39 out of 70 cases (55.7%). A professional sport level was found in 12 cases (17.1%), while a recreational sport level was found in 58 cases (82.9%). Fifty out of 70 cases (71%) were caused by indirect (non-contact) injury (e.g. turning, twisting, or jumping off the planted foot). However, 20 out of the 70 cases (29%) were caused by direct injury.

Lachman test at emergency:

Lachman test at emergency was positive in 27 cases (38.6%) and negative in 27 cases (38.6%). It was clearly difficult to perform a Lachman test in 12 cases (17%). On the other hand, the remaining 4 cases (5.7%) were not examined.

Lachman test under GA (operating room):

Under GA, the Lachman test was positive in 57 cases (81.4%) and negative in 7 cases (10%). The remaining 6 cases (8.6%) were not examined.

Under arthroscopy:

The majority of the cases, (66 [94.3%]) had ACL tears; 55 cases (78.6%) involved total ACL tears, and 11 cases (15.7%) involved partial ACL tears. The ACL was intact in 4 cases (5.7%).

Causes of knee hemarthrosis (Table 3):

Under arthroscopy, the causes of knee hemarthrosis were as follows:

1. ACL was completely ruptured in 55 cases (78.6%) and partially ruptured in 11 cases (15.7%).
2. Isolated total ACL rupture was seen in 22 cases (31.4%).
3. Isolated partial ACL rupture was seen in 11 cases (15.7%).
4. PCL partial rupture was seen in 2 cases (2.9%).
5. Meniscal tears were seen in 50 cases (71.4%) as follows: lateral meniscal (LM) tears in 28 cases (40%) and medial meniscal (MM) tear in 22 cases (31.4%).

Results of combined injuries were as follows:

- ACL + LM in 16 patients (22.9%).
- ACL + MM in 6 patients (8.6%).
- ACL + LM + MM in 3 patients (4.3%).
- ACL + MM + LM + cartilage injury (CI) in 2 patients (2.9%).
- ACL + MCL + LM in 2 patients (2.9%).

Discussion:-

This study confirms the very serious nature of acute traumatic knee hemarthrosis, which is usually represented by an ACL tear that could be undetected unless examined arthroscopically.

We found that examination of patients under GA markedly increased the accuracy of the Lachman test in diagnosing a complete ACL. The data are representative of previous reports that the ACL tear is the most common injury and often occurs as an isolated ligamentous injury (6,7,10).

The current study agrees with DeHaven's study (8) in which the Lachman test has been reported to be a very good test for ACL evaluation. In this study, the Lachman test was a very reliable test for the diagnosis of ACL tear under GA, with positive results in 81.4% of cases. This percentage was relatively high compared with results from Gillquist et al. (4) and Bomberg and McGinty's (7) studies. However, the Lachman test was positive in only 38.6% of patients in the emergency room. This result signifies that performing the Lachman test in an emergency situation is difficult owing to the pain experienced by the patient.

Again, this percentage is relatively high compared with results from Gillquist et al. (4) and Bomberg and McGinty's (7) studies.

Moreover, this study shows that arthroscopy is the best method that can provide an accurate and complete diagnosis in these cases, with the accuracy reaching to 94%. This result is relatively high compared with studies from Gillquist et al. (4), Bomberg and McGinty (7), and DeHaven (6).

Knee joint aspiration in acute ACL injury with suspected hemarthrosis could be considered as a diagnostic procedure (1). So, if we have a patient with knee hemarthrosis in outlying area and we don't have advanced equipments like magnetic resonant image (MRI), we can use arthrocentesis to diagnose the knee injury or at least to classify the injury as a severe injury.

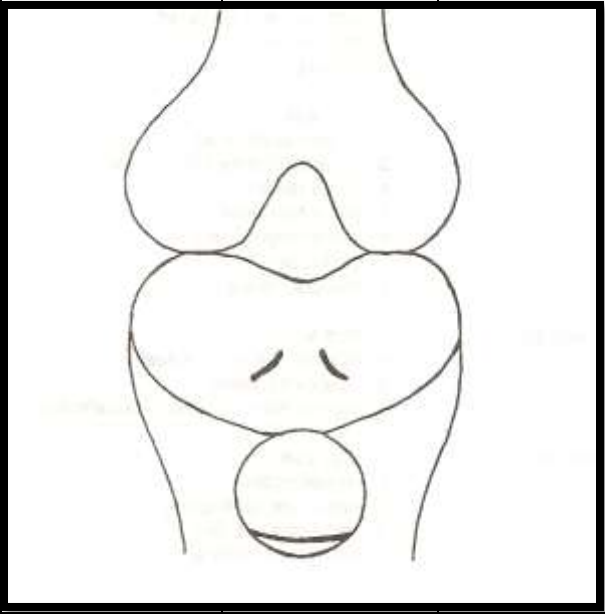
There are a number of limitations that need to be considered. The data was collected only from a single hospital; thus, the results may not be generalizable. The sample size was very small. To overcome these limitations, a larger study that excludes all the limitations should follow.

In summary, aspiration of hemarthrosis in a traumatic knee is a good indicator for ACL injury.

Our results are representative of the reports that ACL tear is the most common injury and often occurs as an isolated ligamentous injury, and noted that combined injuries, such as meniscal tears, chondral injury, PCL tears, and MCL tears, are infrequent causes of posttraumatic hemarthrosis.

Table 1:- Protocol Knee Arthroscopy Case Number.

Medial Compartment	Lateral Compartment	ACL - PCL	M.C.L.	L.C.L.	P.F.J.
-----------------------	------------------------	-----------	--------	--------	--------

Medial Menisci: 1. Normal 2. Longitudinal <1 cm 3. Longitudinal >1 cm 4. Horizontal tear 5. Radial 6. Flap 7. Bucket handle 8. Complex 9. pathological wave 10. Meniscotibial injury Medial Menisci Treatment: 1- Conservative. 2- Partial 3- Subtotal 4- Total 5- Suture 6- Arrows Medial Femoral surface: 1. Normal 2. Grade 1 (fibrillation) 3. Grade 2 (fragmentation) 4. Grade 3 (bone) 5. Cartilage injury (fresh) Medial Tibial surface: 1. Normal 2. Grade 1 3. Grade 2 4. Grade 3	Lateral Menisci: 1. Normal 2. Longitudinal <1 cm 3. Longitudinal >1 cm 4. Horizontal tear 5. Radial 6. Flap 7. Bucket handle 8. Complex 9. pathological wave 10. Meniscotibial injury Lateral Menisci Treatment: 1- Conservative. 2- Partial 3- Subtotal 4- Total 5- Suture 6- Arrows Lateral Femoral surface: 1. Normal 2. Grade 1 (fibrillation) 3. Grade 2 (fragmentation) 4. Grade 3 (bone) 5. Cartilage injury (fresh) Lateral Tibial surface: 1. Normal 2. Grade 1 3. Grade 2 4. Grade 3	ACL: 1. Normal 2. Partial tear 3. Total tear ACL Treatment: 1. Conservative 2. Operative a. Patellar graft b. Hamstring PCL: 1- Normal 2- Partial 3- Total tear PCL Treatment: 1. Conservative 2. Operative Free bodies: 1. Yes 2. No	M.C.L injury 1- Normal 2- Grade 1 3- Grade 2 4- Grade 3 M.C.L Treatment 1. Conservative 2. Operative a. Patellar graft b. Hamstring	L.C.L injury 1- Normal 2- Grade 1 3- Grade 2 4- Grade 3 L.C.L Treatment 1. Conservative 2. Operative	Femoral surface: 1. Normal 2. Grade 1 3. Grade 2 4. Grade 3 Patellar surface: 1. Normal 2. Grade 1 3. Grade 2 4. Grade 3 Patellar Subluxation 1. Yes 2. No
					
Diagnosis					
Procedure					

ACL= Anterior Cruciate Ligament, PCL=Posterior Cruciate Ligament, MCL= Medial Collateral Ligament, LCL=Lateral Collateral Ligament, PFJ=Patellofemoral Joint.

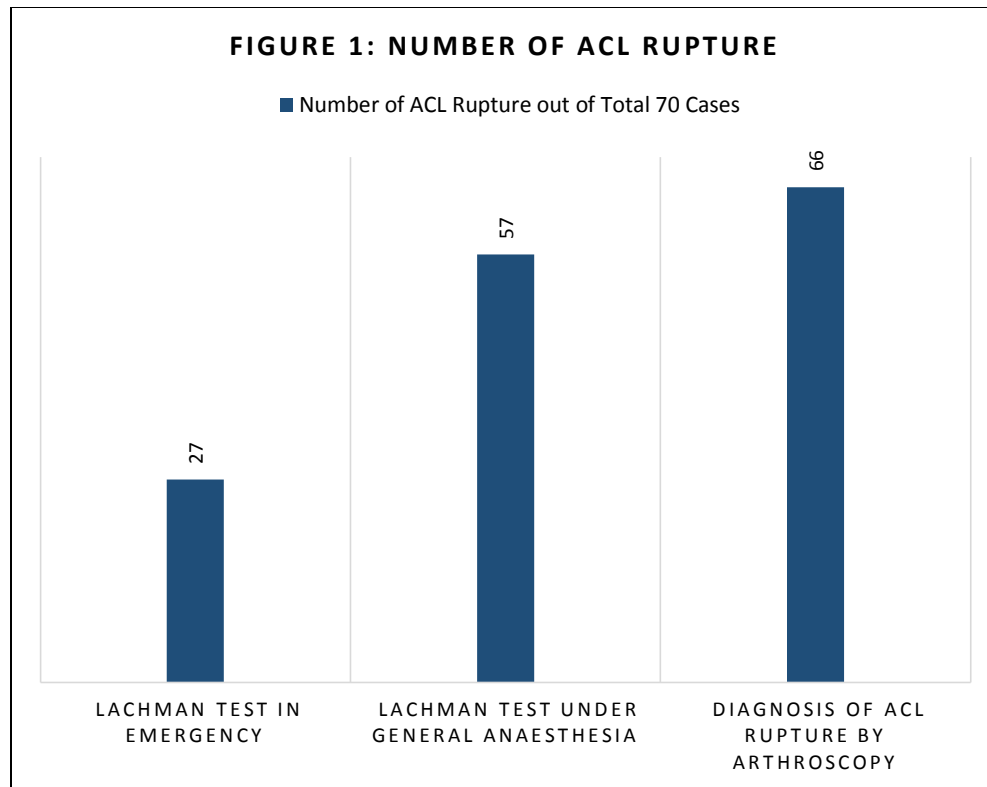


Figure 1:- Number of ACL rupture.

Table 2:- Lachman test findings in the emergency room and under anaesthesia (operation room)

Lachman Test	In Emergency	Under General Anesthesia
Positive Test of ACL	27 Cases (38.6%)	57 Cases (81.4%)
Negative Test of ACL	27 Cases (38.6%)	7 Cases (10%)
Difficult to examine	12 Cases (17%)	0 Cases (0%)
No Examination	4 Cases (5.7%)	6 Cases (8.6%)

Table 3:- Differential diagnosis of knee hemarthrosis and percentage.

Lesion/Injury	Number of Cases	%
ACL:	66 Cases	94.3%
• Total ACL tear	55 Cases	78.6%
• Partial ACL tear	11 Cases	15.7%
Isolated total ACL rupture	22 Cases	31.4%
Isolated partial ACL rupture	11 Cases	15.7%
PCL partial rupture	2 Cases	2.9%
Meniscal tear:	50 Cases	71.4%
• Lateral Meniscus	28 Cases	40%
• Medial Meniscus	22 Cases	31.4%
Combined Injuries:		
• ACL + Lateral menisci (LM)	16 Cases	22.9%
• ACL + Medial menisci (MM)	6 Cases	8.6%
• ACL + Lateral menisci (LM) + Medial menisci (MM)	3 Cases	4.3%
• ACL+Medial menisci (MM)+Lateral menisci (LM)+Cartilage injury (CI)	2 Cases	2.9%
• ACL + MCL (Medial collateral ligament) + Lateral menisci (LM)	2 Cases	2.9%

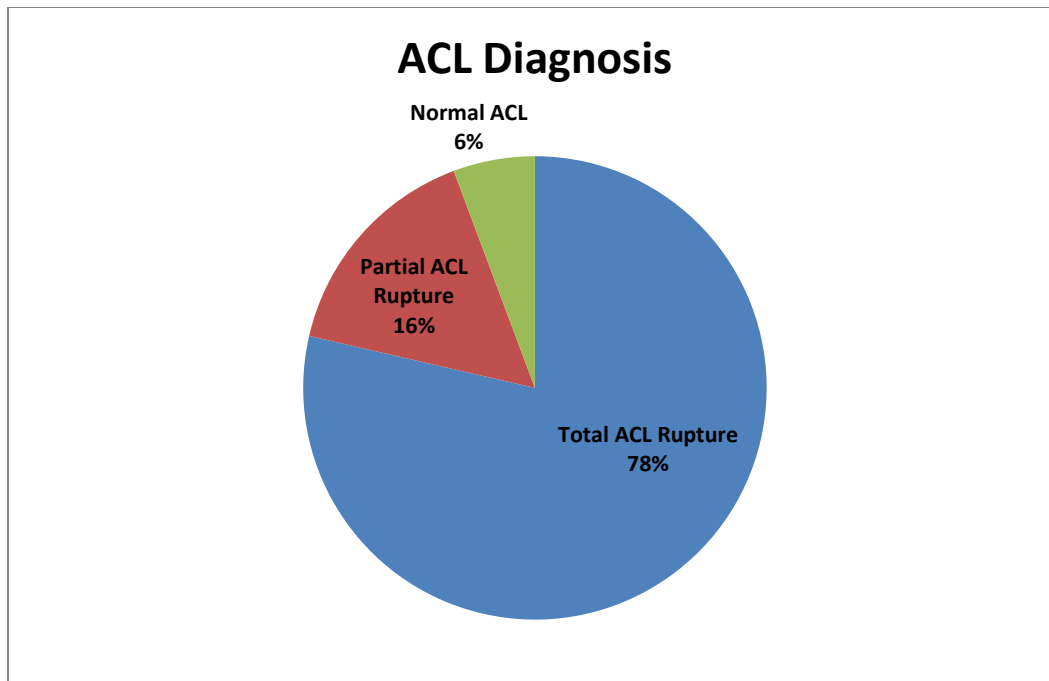


Figure 2:- ACL Diagnosis.

References:-

1. Wang, JH et al., Efficacy of knee joint aspiration in patients with acute ACL injury in the emergency department, *Injury* 2016;47 (8):1744 -9.
2. Journal of Orthopaedic & Sports Physical Therapy, 2011 Volume:41 Issue:10 Pages:749–757 DOI: 10.2519/jospt.2011.3761.
3. Van Eck, C.F., van den Bekerom, M.P.J., Fu, F.H. et al. *Knee Surg Sports Traumatol Arthrosc* (2013) 21: 1895.
4. Gillquist J, Hagberg G, Oretorp N. Arthroscopy in acute injuries of the knee joint. *Acta Orthop Scand* 1977;48:190-6.
5. Noyes FR, Bassett RW, Grood ES, Butler DL. Arthroscopy in acute traumatic hemarthrosis of the knee. *J Bone Joint Surg [Am]* 1980;62:687-95.
6. DeHaven KE. Arthroscopy in the diagnosis and management of the anterior cruciate ligament deficient knee. *Clin Orthop* 1983;172:52-6.
7. Bomberg, BC, McGinty JB. Acute hemarthrosis of the knee indications for diagnostic arthroscopy, *Arthroscopy* 1990;6:221-5.
8. Gelb HJ, Glasgow SG, Sapega AA, Torg JS. Magnetic resonance imaging of knee disorders. Clinical value and cost-effectiveness in a sports medicine practice. *Am J Sports Med* 1996;24:99-103.
9. Classification of meniscal tears. *OrthopaedicsOne Articles*. In: *OrthopaedicsOne - The Orthopaedic Knowledge Network*. Created Apr 18, 2012 06:51. Last modified Apr 18, 2012 07:42 ver.232.
10. Bergstrom R, Gillquist J, Lysholm J, Hamberg P. Arthroscopy of the knee in children. *J Pediatr Orthop* 1984;4:542-5.
11. DeHaven KE. Meniscus repair in the athlete. *Clin Orthop* 1985;198:31-5.
12. DeKeizer G. Acute arthroscopy in posttraumatic hemarthrosis of the knee joint. *Neth J Surg* 1983;35:94-6.
13. Donaldson WF, Warren RF, Wickiewicz T. A comparison of acute anterior cruciate ligament examinations: initial versus examination under anesthesia. *Am J Sports Med* 1985;13:5-10.
14. Gelb HJ, Glasgow SG, Sapega AA, Torg JS. Magnetic resonance imaging of knee disorders. Clinical value and cost-effectiveness in a sports medicine practice. *Am J Sports Med* 1996;24:99-103.
15. Glashow JL, Katz R, Schneider M, Scott WN. Double-blind assessment of the value of magnetic resonance imaging in the diagnosis of anterior cruciate and meniscal lesions. *J Bone Joint Surg [Am]* 1989;71:113-9.
16. Kannus P, Jarvinen M. Long-term prognosis of nonoperatively treated acute knee distortions having primary hemarthrosis without clinical instability. *Am J Sports Med* 1987;15:138-43.

17. Kocabey Y, Tetik O, Isbell WM, Atay OA, Johnson DL. The value of clinical examination versus magnetic resonance imaging in the diagnosis of meniscal tears and anterior cruciate ligament rupture. *Arthroscopy* 2004;20:696-700.
18. Lundberg M, Odensten M, Thuomas KA, Messner K. The diagnostic validity of magnetic resonance imaging in acute knee injuries with hemarthrosis. A single-blinded evaluation in 69 patients using high-field MRI before arthroscopy. Department of Orthopedics and Sports Medicine, University Hospital, Linköping, Sweden. *Int J Sports Med* 1996;17:218-22.
19. Morrissy RT, Eubanks RG, Park JP, Thompson SB. Arthroscopy of the knee in children. *Clin Orthop* 1982;162:103-7.
20. Noyes FR, Mooar LA, Moorman CT, McGinnis GH. Partial tears of the anterior cruciate ligament. *J Bone Joint Surg [Br]* 1989;71:825-33.
21. Paessler HH, Michel D. How new is the lachman test? *Am J Sports Med* 1992;20:95-8.
22. Sarimo J, Rantanen J, Heikkilä J, Helttula I, Hiltunen A, Orava S. Acute traumatic hemarthrosis of the knee. Is routine arthroscopic examination necessary? A study of 320 consecutive patients. *Scand J Surg* 2002; 91:361-4
23. Simonsen O, Jensen J, Mouritsen P, Lauritzen J. The accuracy of clinical examination of injury of the knee joint. *Injury* 1984;16:96-101.
24. Maffulli N, Binfield PM, King JB, Good CJ. Acute haemarthrosis of the knee in athletes. A prospective study of 106 cases. *J Bone Joint Surg Br* 1993;75:945-9.